

Patient DF

Pulseless left hand after
motorcycle crash

History of Present Illness

- 45 year old gentleman driver of motorcycle sustained high speed accident after colliding with a car at a high rate of speed complaining of chest pain and left shoulder pain.
- He had transient hypotension at the scene.

Medical History

- Past Medical Problems - None
- Past Surgical History - Previous motorcycle crash with multiple rib fractures and splenectomy
- Medications - None
- Allergies - None
- Social History - No alcohol, tobacco or drug use

Physical Examination

- Vital Signs
 - BP 118/74
 - Pulse 120
 - Resp 22
 - Temp 36.8
- General: Awake and alert in severe distress secondary to pain
- HEENT- Normal
- Neck - Nontender, C-collar in place
- Chest - Tender over left chest, bilateral and equal breath sounds

Physical Examination

- Abdomen - Well healed long midline scar, normal bowel sounds, nontender.
- Back - Nontender without deformity
- Pelvis - Stable to AP compression, nontender
- GU- Normal
- Rectal - Normal sphincter tone, prostate normal, heme -

Physical Examination

- Neuro-Awake and alert, GCS 15, PERRL, EOMI, CN's intact, normal motor and sensory exam.
- Ext- Left upper - No pulse in left arm, weak biphasic doppler signal, Capillary refill = 2 seconds, median and ulnar nerves - No function, Radial-Weak wrist extension.

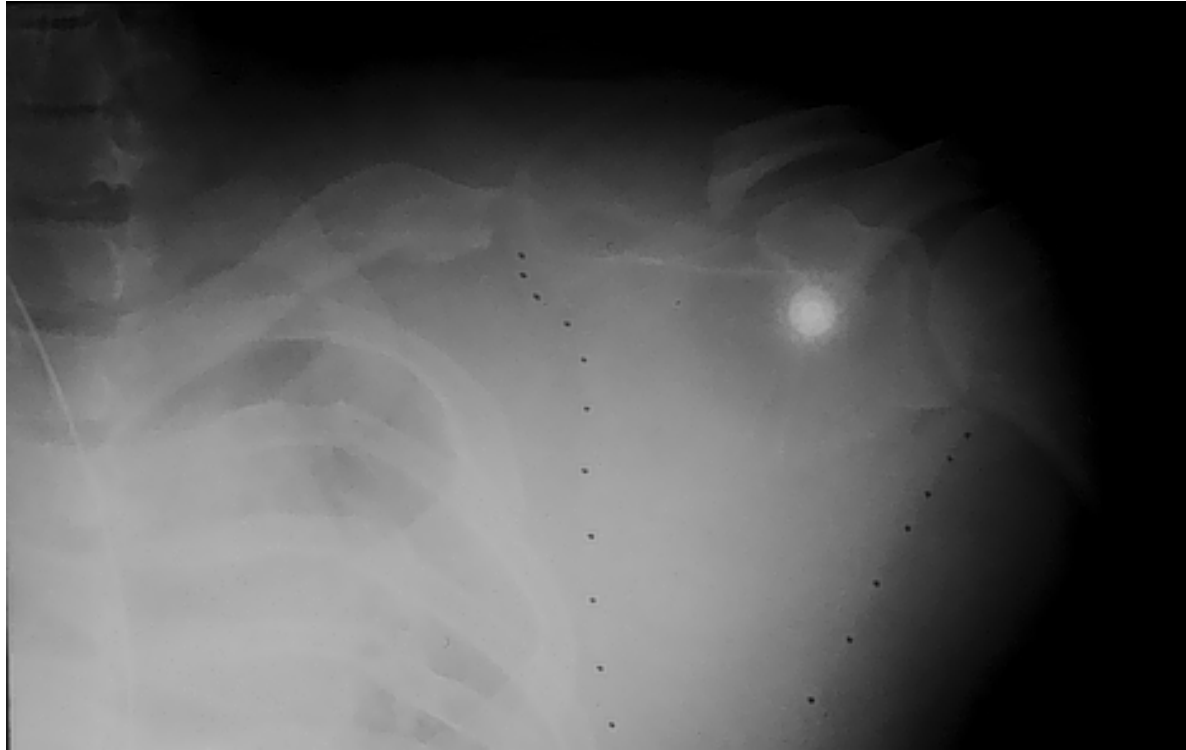Laboratory

- Hematocrit - 36
- WBC - 17,000
- Amylase 54
- ABG - pH 7.31 PO₂ 245 PCO₂ 34 BE -6
- Urinalysis - Normal

Diagnostics: XRays

- CXR - Scapulothoracic disassociation, No pneumo or hemothorax
- C-spine - Normal to C6
- Pelvis - Normal

Diagnostics: X Rays

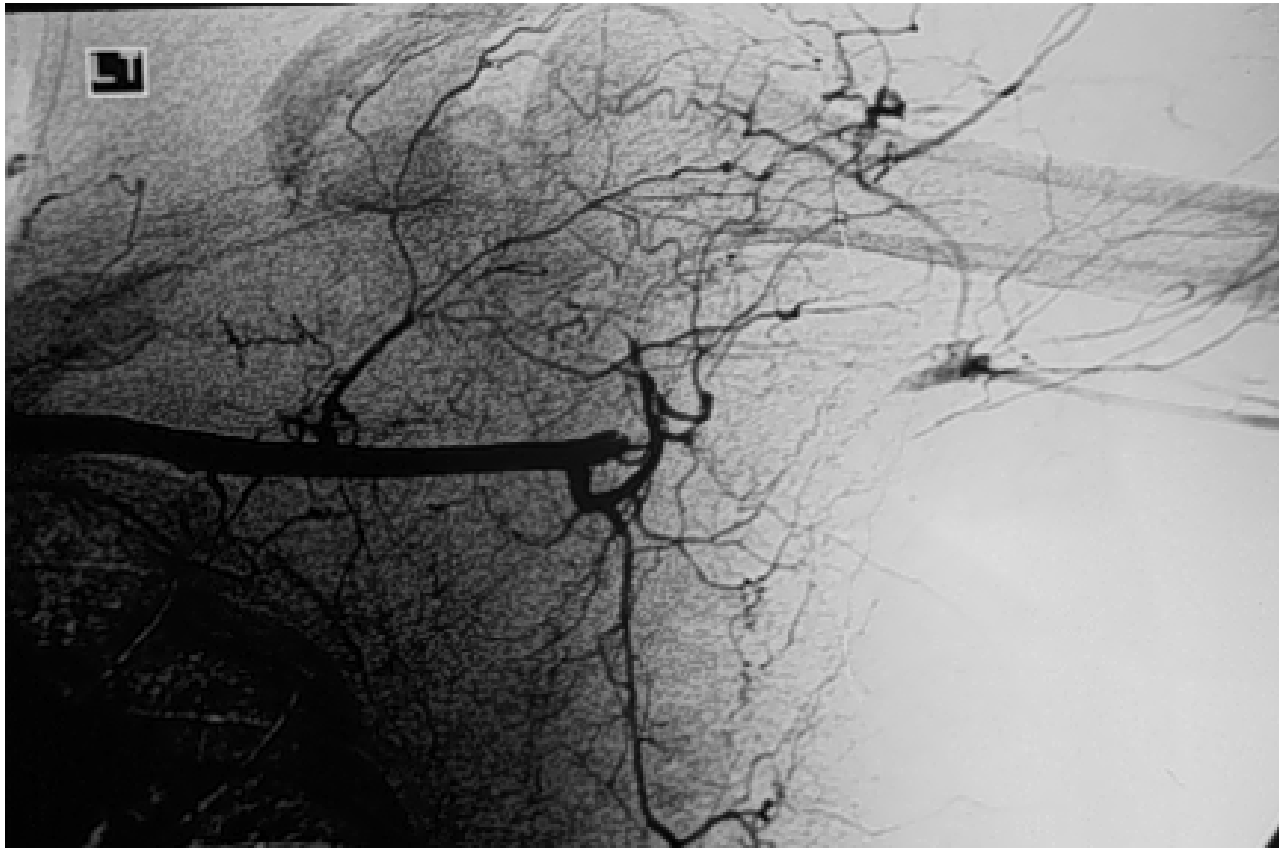


Scapulothoracic dissociation with clavicular fracture and probable axillary artery and brachial plexus injury.

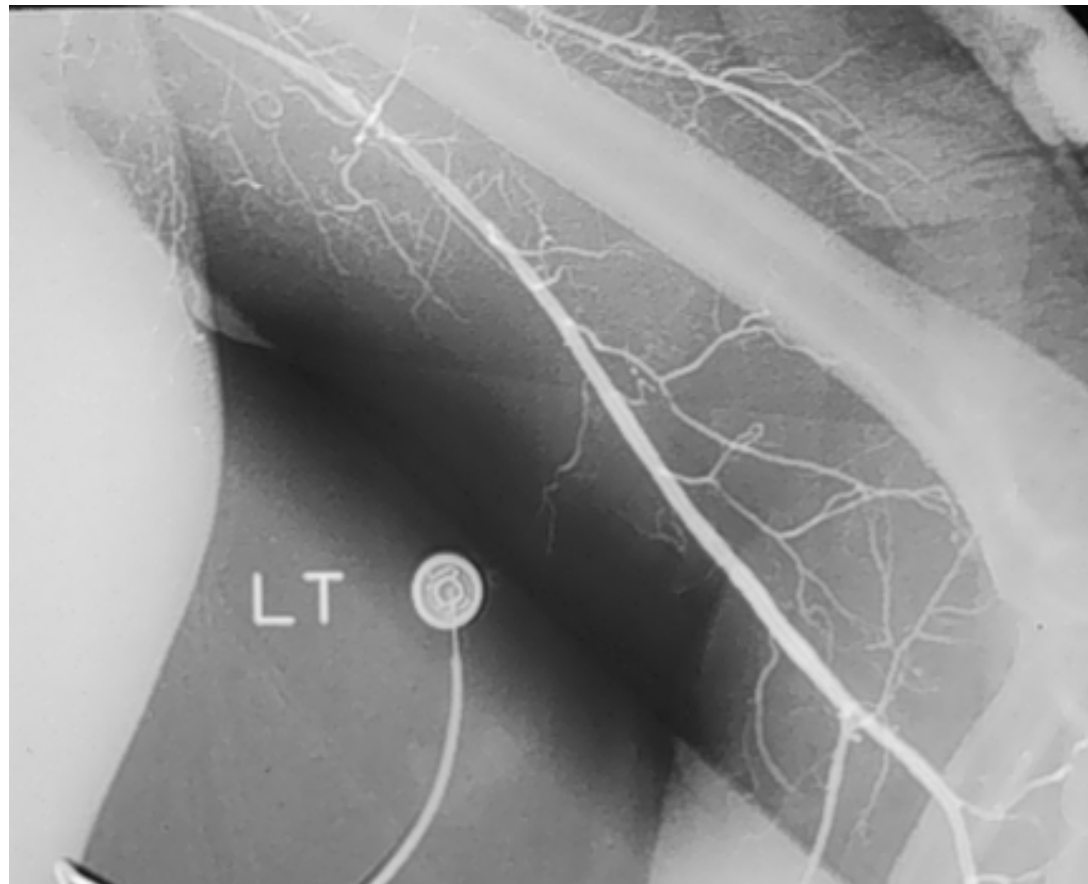
Plan

- Aortic arch, axillary and brachial arteriography to rule out aortic injury and define anatomic injury
- To the Operating Room following arteriography for vascular repair, assessment of brachial plexus and open reduction with internal fixation of the clavicle

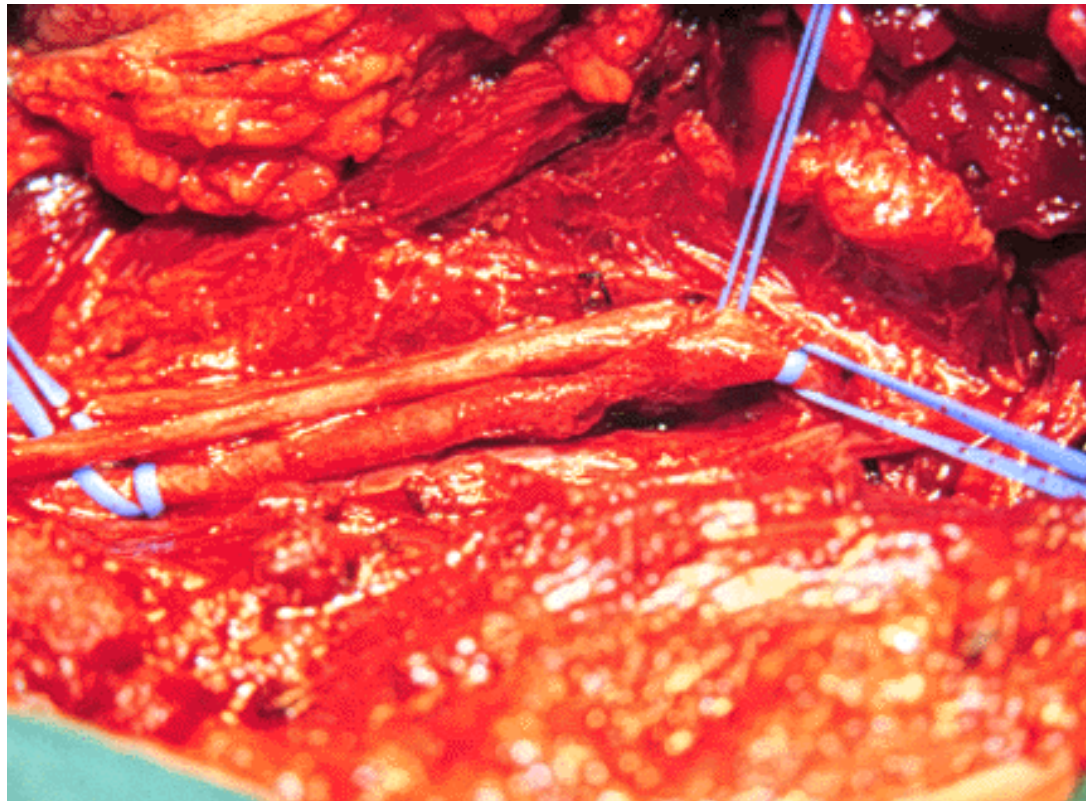
Diagnostics: Axillary Arteriogram



Diagnostics: Brachial Arteriogram



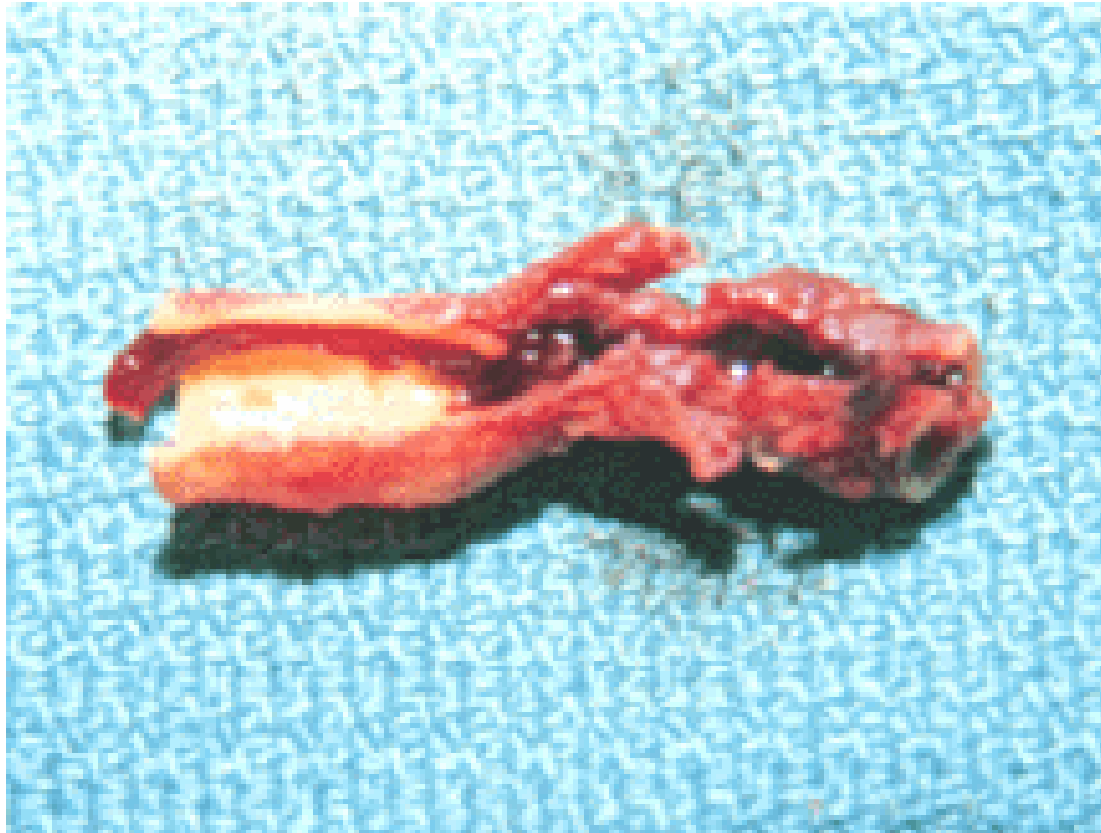
Operating Room



Operating Room: Findings

- Thrombosed distal axillary artery with blunt vascular injury
- Intact but very tense brachial plexus.
- Scapular fracture
- Intact subclavian vein

Excised Segment of Artery



Procedures

- Excision of injured axillary artery with repair with reverse saphenous vein graft
- Reduction of shoulder
- Internal fixation of clavicle fracture

Hospital Course

- Return of normal pulses
- Soft forearm compartments
- Extubated on the night of surgery
- Transferred out of the intensive care unit on postop day #2

Hospital Course

- Rehabilitation for neurologic injury begun immediately
- Discharged to rehabilitation facility on postop day #10